

Clinical Pathologic Correlations of Lyme Disease

Paul H. Duray

From the Department of Pathology,
Fox Chase Cancer Center,
Philadelphia, Pennsylvania

The multisystem effects caused by *Borrelia burgdorferi* in Lyme disease are multiple, varied, and unpredictable. In some patients, the full extent of the infection consists of a stage I acute systemic viral-like illness. Stage II primarily involves the cardiovascular system (myocarditis) and/or the central nervous system (CNS) (meningoencephalitis, polyradiculitis). More inflammatory cells are found in the heart and nervous system structures during this intermediate stage than are found in any tissues involved during stage I. Stage III is characterized by peripheral neuropathy and CNS disorders such as dementia or transverse myelitis and arthritis and synovitis of large joints such as the knee. Chronic Lyme disease is also associated with multiple and seemingly unrelated cutaneous manifestations such as acrodermatitis chronica atrophicans, sclerodermoid-like reactions, lichen sclerosus et atrophicus, subcuticular fibrous nodules, eosinophilic fasciitis-like lesions of the extremities, and, possibly, granuloma annulare. With care, spirochetes can be recovered or demonstrated by silver staining in most of the above lesions. Spirochetes have yet to be seen in the tissues of autonomic ganglia or peripheral nerves.

The past 4 years have seen a dramatic increase in the spectrum of tissue and organ damage attributed to *Borrelia burgdorferi* infection in humans [1, 2]. Lyme disease has now been shown to involve nearly every organ and organ system in both sexes. Initially thought to be a disorder beginning in the skin and progressing to involve the joints, Lyme disease is now ranked as one of the great mimickers of other diseases, in a manner similar to that once ascribed to syphilis. Even concepts of the well-known pathognomonic skin lesion, erythema chronicum migrans (ECM), have changed in recent years [3-5]. For example, it is now known that ECM can become multiple in the initial stage and can recur years after the initial infection [3].

The course of Lyme disease varies significantly from patient to patient [6]. Stage I, the initial (and sometimes only) phase of the disease, consists of an acute systemic viral-like illness usually heralded by ECM [6, 7]. The intermediate stage II primarily involves the heart (myocarditis) and/or the CNS (meningoencephalitis) [8, 9]. It is still not understood why some patients present with isolated manifestations of chronic stage III disease such as advanced neuropathy, arthritis, or a specialized chronic cutaneous syndrome without having presented evidence

of previous infection such as ECM, meningitis, or myocarditis.

Staging of Lyme disease is not a clear-cut matter, since both the timing and the clinical features of the different stages may overlap in some patients. Further complicating the staging of this infection is the fact that serologic tests often do not show any correlation between titer and extent of damage to organ systems. Nonetheless, staging provides a framework for studying and correlating the clinical and pathologic aspects of the infectious syndrome. The extent of organ and tissue damage in Lyme disease, as determined by clinical pathologic review, is summarized in this report.

Materials and Methods

Most of the 40 cases studied are from the files of the Rheumatology Clinic and Pathology Department at the Yale-New Haven Hospital. In addition, cases from Sweden, the Netherlands, France, West Germany, Yugoslavia, Hungary, and Austria, as well as others sent in consultation from across the United States, were reviewed.

Slide review was performed on submitted glass slides unless formalin-fixed paraffin-embedded tissues were available, in which case further sections were studied with standard hematoxylin and eosin stain, periodic acid-Schiff stains, stains for fibrin and fibrinogen, the trichrome stain, elastic tissue

stains, amyloid stains, and mast cell stains. Electron microscopy was employed where applicable. A modified Dieterle stain was used to demonstrate tissue spirochetes. Silver reduction time was recently shortened to 15 minutes by use of a microwave technique.

Avidin-biotin immunohistochemical techniques were used to verify the presence of *B. burgdorferi* when paraffin blocks were available. Monoclonal antibodies used included H5332 and H3TS (these monoclonal antibodies were a gift from Dr. A. Barbour, University of Texas, San Antonio). A hyperimmune polyclonal rabbit serum was also used in addition to *B. burgdorferi*-specific monoclonal antibodies.

Acute Stage (Stage I)

Pathogenesis and cutaneous manifestations. Humans generally acquire Lyme disease when an infected female *Ixodes dammini* tick, particularly one in its nymphal stage, feeds for at least 4 to 6 hours through the skin. Direct spirochete transfer into the microvasculature of the skin no doubt occurs (figure 1), but the primary ECM lesion reflects the presence of spirochetes in the dermis accompanied by a perivascular infiltrate of plasma cells, lymphocytes, macrophages, and (rarely) mast cells [10]. Except for a slight swelling, vascular endothelium does not appear to be damaged at this stage.

With care, spirochetes can be found in any layer of the dermis [11] and, on occasion, in the epidermis. The spirochete form at this stage of the disease can be either short or elongate. The epidermis remains intact, and except at the immediate site of the tick bite papule, there is no collagen necrosis.

Clinically, ECM classically shows central clearing with a hyperemic rim [4, 12]. However, solid red, irregularly shaped lesions or even urticaria or skin blotches may occur.

Lymphocytoma cutis, a form of lymphocytic hyperplasia—defined as well-delineated lymphoid follicles with germinal centers (figure 2)—can occur in the acute stage and, if the patient is not properly diagnosed and treated, may persist into later stages of the disease. Lymphocytoma cutis is seen primarily in Europe, where it has recently been renamed borrelial lymphocytoma [13]. Peculiar in its appearance and in its predilection for the inferior ear lobes and the skin of the nipple, borrelial lymphocytoma appears to be associated with a B cell response to the presence of *B. burgdorferi* and its antigens.

Systemic involvement. The Lyme spirochetes enter the circulation via the skin vasculature. As the organisms disperse through the vascular system, primarily via the venous route, patients develop a systemic flu-like syndrome reflected by fever, vomiting, joint aches, myalgia, and (occasionally) photophobia or conjunctivitis [14]. Some of these manifestations are undoubtedly related to the production of lymphokines (such as the interleukins and interferon) and other modifiers of biologic response [15].

In this acute spirochetemic phase, the pathogens can disseminate to any organ but appear to have a predilection for the reticuloendothelial system. Thus, generalized or regional lymphadenopathy (figure 3), splenomegaly, anicteric hepatitis, and orchitis may accompany the flu-like symptoms in some patients. As in infectious mononucleosis, the enlargement of the spleen may, on rare occasion, be associated with splenic rupture, which creates an acute surgical condition such as occurred recently in a patient from Connecticut (author's unpublished data).

All of the involved viscera in this acute phase contain inflammatory infiltrates characterized by mononuclear cells, lymphocytes, and plasma cells. With a careful search and the preparation of multiple sections, it also is possible to demonstrate spirochetes by silver staining.

The signs and symptoms of the acute stage I illness occur anywhere from several days to about 6 or 7 weeks after the transfer of the spirochete from the feeding tick to the human host. Not only is there great variation within this time frame as to when the various manifestations of stage I will occur but there is equal variation in terms of their clinical presentation, since they can occur with great severity in some patients, not at all in others, and to all degrees in between.

Intermediate Stage (Stage II)

While the infectious syndrome may progress no further than the stage I manifestations just discussed, a significant number of patients progress to an intermediate phase that primarily involves the cardiovascular and nervous systems. Stage II involvement makes its appearance anywhere from 1 month to 8 or 9 weeks after the initial infection. By the time this stage begins, lymphadenopathy, splenomegaly, and signs of hepatitis and orchitis will have abated.

CNS and peripheral nerve involvement. While patients in stage I may have severe headaches, there

is usually no pleocytosis until the onset of stage II disease. Frank signs of meningeal irritation herald stage II illness, reflected by an increase in CSF lymphocytes and plasma cells and moderate increases in total protein in CSF [9, 16, 17]. Immature B cells can also be seen in the spinal fluid. These cells can appear quite atypical—not unlike those of transformed or neoplastic lymphocytes. Although it is known that spirochetes can be isolated from the spinal fluid, they are not recovered in all cases.

CNS disease has rarely been observed histopathologically, but our limited experience has shown that there are scattered perivascular mononuclear cell infiltrates in the cerebral cortex (figure 4), sometimes accompanied by mild, spongiform changes, an increase in microglial cells focally, and a modest infiltrate of lymphocytes and plasma cells in the leptomeninges. Necrosis has not been encountered in CNS tissues. Spirochetes have been seen as sparse single organisms in brain tissue after prolonged microscopic search (figure 5). Colonies of spirochetes have not been found.

Paresis of any of the nerves innervating the face can occur in this intermediate stage, but the nerves predominantly involved have been the oculomotor and facial nerves [18, 19]. Bell's palsy, particularly in bilateral form, is seen with some degree of frequency [18, 19]. Microscopic examination reveals that lymphocytes and plasma cells directly infiltrate the autonomic ganglia and the nerves themselves. This infiltration is accompanied by thickening of the perineural blood vessels, themselves rimmed at times by inflammatory cells. To date, this author has not observed spirochetes in peripheral nerves or in autonomic ganglia.

The duration of the CNS manifestations of stage II Lyme disease is usually short and can be shortened further by appropriate antibiotic therapy. It is interesting that many patients do not recall any acute or stage I-type illness and may present with Bell's palsy or a meningitis-like syndrome as an isolated event. Patients in this intermediate stage may also manifest peculiar signs of cerebral dysfunction in the form of personality changes or even as severe episodes of drowsiness or stupor. The diagnosis can generally be made by serologic testing or by identifying Lyme antibodies in the CSF.

Cardiovascular involvement. Initially it was thought that ~8% of patients with Lyme disease would develop Lyme myocarditis [8]. However, a higher percentage of patients may actually be af-

ected by this stage II manifestation, which is characterized clinically by tachycardia and either complete or incomplete heart blockage. Tachycardia with arteriovenous junctional blockage is a disturbing manifestation, but patients with this complication appear to do surprisingly well.

Endocardial biopsy via the transvenous route into the right ventricle predictably shows a band-like infiltrate of lymphocytes and plasma cells in the endocardium. This is in contrast to the inflammatory pattern seen in cell-mediated rejections of heart transplants. Deeper biopsies have shown an interstitial myocarditis (figure 6), and in one terminally ill patient, a transmural infiltrate of lymphocytes and plasma cells from the endocardium to the epicardial surface was demonstrated.

As with stage II CNS manifestations, cardiovascular involvement is usually of relatively short duration and can be shortened further by use of appropriate antibiotics. Again, as with CNS manifestations, cardiovascular complications may present in patients with no known antecedent signs or symptoms of Lyme disease.

Deep myositis. Manifestations of a deep myositis are now being seen with increasing frequency in both Europe and the United States [20]. Patients may develop this complication anywhere from 7–8 weeks up to ~5 months after initial infection. Clinically, deep myositis is characterized by painful episodes accompanied by swelling of proximal muscles, particularly the thigh musculature. While this can be fleeting in nature, it may also be present continuously for several months. Biopsy specimens show collections of lymphocytes and plasma cells tightly packed around branches of the intramuscular veins. This is similar to the picture seen in polymyositis and even in dermatomyositis. The muscle fibers themselves do not appear to be damaged, at least when examined by light microscopy. With careful searching spirochetes can be demonstrated in specimens taken from the deep muscle.

A continuing problem. The cutaneous complication of borrelial lymphocytoma can spill over into the intermediate stage II. If it continues to be unrecognized and untreated, it will also be found even later in the illness.

Chronic Lyme Disease (Stage III)

Lyme borreliosis that continues for many months or even years is classified as stage III, or chronic

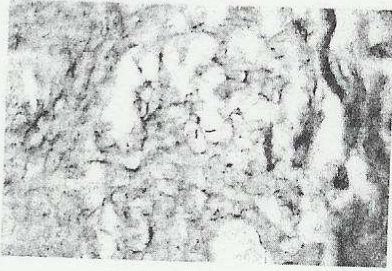


Figure 1




Figure 2

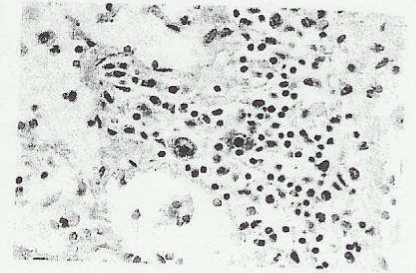


Figure 3

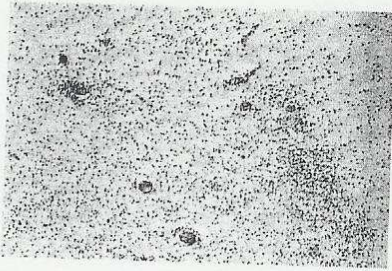


Figure 4



Figure 5




Figure 6

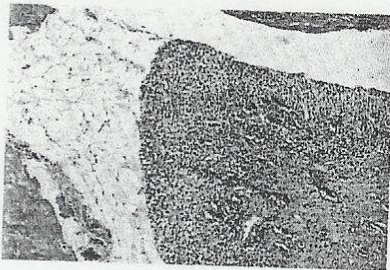


Figure 7




Figure 8




Figure 9




Figure 10




Figure 11

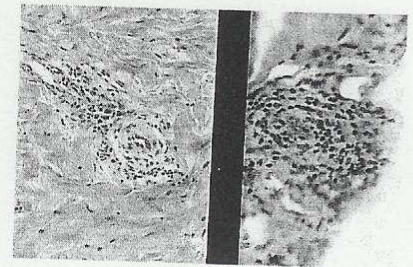


Figure 12

Figure 1. Erythema migrans showing two short spirochetes in the center of the photomicrograph. The collagen is not damaged in this acute stage I lesion (Dieterle stain). **Figure 2.** Typical lymphoid follicle with germinal center, a constant feature of borreliac lymphocytoma. **Figure 3.** Photomicrograph of lymph node in stage I Lyme borreliosis. Note characteristic large precursor B cell in the center. **Figure 4.** Low-power photomicrograph of perivascular inflammatory and microglial cells in the cerebral cortex. This finding is not always present in Lyme disease. **Figure 5.** Brain tissue of a hamster showing a single spirochete. The morphology of the organism in this example is typical of *Borrelia burgdorferi* (Dieterle stain). **Figure 6.** Photomicrograph of Lyme myocarditis showing typical interstitial infiltrate of lymphoid cells. **Figure 7.** Synovial villus showing hyperplastic synovial lining cells and lymphocytes. **Figure 8.** Low-power magnification of curetted synovia in a patient with Lyme arthritis. The green shows the collagen of the synovia, while the red material is fibrin (Trichrome stain). **Figure 9.** Lyme arthritis showing characteristic findings. **Figure 10.** Photomicrograph showing findings in Lyme arthritis. **Figure 11.** Photomicrograph showing findings in Lyme arthritis. **Figure 12.** Photomicrograph showing findings in Lyme arthritis.

Lyme disease [21]. This stage is characterized mainly by involvement of the joints, skin, and peripheral nervous system [14]. As in earlier stages, lymphocytes and plasma cells are found in abundance in involved tissues, even in lesions that have been present for many years. The continuing presence of plasma cells suggests that spirochetes are present and survive for long periods. We now know that this is indeed the case and that spirochetes can be maintained in some of these sites, particularly the skin, for years [22, 23].

Arthritic manifestations. Lyme disease was initially described in North America as epidemic oligoarthritis with a particular affinity for younger patients [24]. It was, in fact, this arthritis that caused most patients to seek medical attention, largely because of the substantial disability associated with involvement of the knee, the joint most often affected. Knee involvement was usually accompanied by swelling about the joint. This was caused by a marked proliferation of the synovial soft tissues, with or without an increase in joint fluid.

Pathologically, the synovial membrane may proliferate into villous fronds with hyperplasia of cells of the synovial lining that extend into the underlying stroma [25] (figure 7). This is often accompanied by dense aggregates of lymphocytes in a near follicular arrangement but without the well delineated germinal centers seen in rheumatoid arthritis. Giant cells and necrobiotic granulomas have not been observed in Lyme synovitis. Plasma cells are abundant, as are mast cells. Edema is variable—present to a significant degree in some patients and totally absent in others.

Deposits of fibrin and fibrinogen, either on the surface of the synovial membrane or within the stroma itself, occur in a number of patients [25] (figure 8). While these deposits are not specific for Lyme arthritis, their presence, accompanied by thickening of the walls of synovial vessels—especially if the thickening totally obliterates the vascular lumen—

is strongly indicative of the illness (figure 9). In fact, on several occasions, such findings on laboratory examination have led to a diagnosis of Lyme disease, even in the absence of clinical information. Spirochetes can rarely be seen within synovial tissues [25].

Nervous system involvement. Biopsy of the sural nerve in patients with peripheral neuropathy associated with chronic Lyme disease has demonstrated the presence of lymphocytes and plasma cells in the nerve itself as well as in the perineural region (figure 10). This is not dissimilar to the pattern of infiltrates seen in stage II. What differentiates this complication from stage II involvement, however, is its apparent permanence. It can persist for years. With time, the vessels outside the nerve sheath become thickened and obliterated as do synovial vessels, a situation that suggests a component of ischemic damage may contribute to the neuropathy of chronic disease. Fibers within the nerve eventually lose myelin, a finding that has been demonstrated in both human patients and experimental animals. There is also evidence that a transverse myelitis of the spinal cord, suggestive of the Guillain-Barré syndrome, may be involved in some chronic infections. Stage III involvement of cerebral parenchyma may manifest itself as dementia or other forms of psychiatric illness.

Cutaneous complications. Multiple and varied complications involving the skin and hypodermis occur in chronic and unremitting Lyme disease. These complications appear to be more common in Europe than in the United States, although increased clinical awareness of these manifestations by European clinicians may be the reason for this reported difference.

The classic model for chronic cutaneous involvement in Lyme disease is acrodermatitis chronica atrophicans (ACA), which is manifested primarily by a unique discoloration of the acral skin of the hands and wrists or feet and ankles [26]. This discoloration (which usually ranges from a deep rubor

synovitis. In this case, there is stromal edema and a single occluded vessel. **Figure 10.** Photomicrograph of a sural nerve showing infiltration by lymphocytes and scattered plasma cells in a patient with peripheral neuropathy. **Figure 11.** Photomicrograph of acrodermatitis chronica atrophicans showing loss of rete ridges at the top of the figure and a heavy infiltrate of lymphocytes, plasma cells, macrophages, and scattered mast cells. The inflammation is more intense than that found in erythema chronicum migrans. **Figure 12.** Deep skin biopsy in a patient with longstanding cutaneous manifestations of Lyme borreliosis. The left panel shows an occluded vessel in the hypodermis accompanied by moderately intense plasma cells and lymphocytes, while the right panel shows the thickened bands of collagen in the deep dermis.

to a faint mauvish-pink but which may also be violaceous) is usually accompanied by what appears, macroscopically, to be an atrophy of the skin. While this involvement is usually bilateral, unilateral involvement has been seen. When the involvement is unilateral, an underlying neuropathy can be present in the affected limb.

Histopathologically, the epidermis in ACA may have lost the rete ridges or may show acanthosis [26] (figure 11). Vessels are dilated, and there are numerous lymphocytes, macrophages, plasma cells, and mast cells intervening in the dermis between the dilated vessels. The infiltrate can spill into the underlying fat and surround blood vessels, much as was seen in other tissues in the more acute stages. If ACA occurs on the upper extremities, unique soft-tissue nodules, referred to as ulnar fibrous nodules, can be found around the elbow joints. Pathologic examination reveals these nodules to be filled with collagen, macrophages, and plasma cells. Surrounding capillaries may also be occluded by similar deposits. A combination of ulnar fibrous nodules and ACA is strongly indicative of Lyme disease, this being an even tighter association than the presence of thickened vessels and fibrin deposits in the joint synovia. As with ACA alone, this combination appears to be more common in European than in North American patients. Organisms can be demonstrated in both ACA lesions and in the fibrous nodules.

Increasing experience shows that the hallmark of the acute stage, ECM, can, and does, occur years later as some form of reinfection. There is some evidence that the organism may induce a new form of ECM related in some way to the presence of ACA in chronic disease. This may also occur as a result of a newly acquired infection, thus providing evidence that prior infection and recovery do not confer long-term immunity [3, 27].

Recently defined cutaneous expressions of chronic Lyme disease include sclerodermoid lesions having, as a common denominator, a thickened dermis due to increased collagen. There is an expansion of the reticular dermis by widened bands of collagen that extend beyond the eccrine sweat coils into the underlying fatty subcutis. Various amounts of perivascular lymphoid and plasma cell infiltrates are present in some of the lesions, no matter how long the disease has been present. To date, we have seen no clinical expressions that resemble progressive systemic sclerosis (i.e., no interstitial fibrosis of the lungs, gastrointestinal tract, or kidneys, although all

of these cutaneous lesions have been histologically indistinguishable from morphea, or localized scleroderma).

Also seen as cutaneous manifestations of chronic Lyme disease are areas of localized firmness of the skin that prove to be immobile when palpated and that show, on biopsy, vascular lymphoid and plasma cell infiltrates extending into the hypodermis and involving the underlying fascia (figure 12). These lesions are also associated with perivascular infiltrates in the underlying muscle. An increase in mast cells, eosinophils, and macrophages has been observed in involved tissues, as is seen in eosinophilic fasciitis, or Shulman's disease. However, these patients do not seem to have peripheral blood eosinophilia.

Yet another cutaneous entity involved in chronic Lyme disease is a lesion that, for all intents and purposes, is identical to that of lichen sclerosus et atrophicus. Just as occurs in the patient with non-Lyme lichen sclerosus, amorphous collagen deposition is found in the Lyme-associated look-alike in the papillary dermis, subjacent to which is a band-like infiltrate of lymphoid cells. There are various degrees of thickening in the reticular dermis. We have seen this change in two North American patients; it has been observed more frequently in Europe than in the United States.

It is obvious that many varied and seemingly unrelated chronic cutaneous syndromes can now be associated with chronic or stage III Lyme disease. However, the pathogenesis of these syndromes remains an enigma, and further study is required to elucidate their exact relationship to the underlying infection.

Conclusion

The multisystem involvement of Lyme disease during the various stages of illness contributes to the protean clinical manifestations and complex histopathologic features of the infection. While it is not well understood why the presentation of the disease is so variable, there is clear evidence that the causative spirochete can persist for months or even years in many human tissues and is thus responsible for the strange and often unique manifestations of late, as well as earlier, disease. With that as a given, it is clear that antimicrobial therapy is indicated for the Lyme disease patient no matter what the stage of the illness—acute, intermediate, or chronic.

